

RESEARCH ARTICLE

Death metal: Evidence for the impact of lead poisoning on childhood health within the Roman Empire

Joanna Moore¹  | Kori Filipek¹  | Vana Kalenderian²  | Rebecca Gowland¹ | Elliott Hamilton³ | Jane Evans³ | Janet Montgomery¹

¹Department of Archaeology, Durham University, Durham, UK

²Groningen Institute of Archaeology, University of Groningen, Groningen, Netherlands

³National Environmental Isotope Facility, British Geological Survey, Keyworth, UK

Correspondence

Joanna Moore, Department of Archaeology, Durham University, Durham, DH1 3LE, UK.
Email: j.f.moore@durham.ac.uk

Funding information

NERC IAPETUS, Grant/Award Number: NE/L002590/1

Abstract

The use of lead was ubiquitous throughout the Roman Empire, including material for water pipes, eating vessels, medicine, and even as a sweetener for wine. The toxicity of lead is well established today, resulting in long-term psychological and neurological deficits as well as metabolic diseases. Children are particularly susceptible to the effects of lead, and it is likely that the widespread use of this deadly metal among Roman populations led to a range of adverse health effects. Indeed, lead poisoning has even been implicated in the downfall of the Roman Empire. This research examines, for the first time, the direct effect of lead poisoning on the inhabitants of the Empire. It explores whether the dramatic increase in lead during this period contributed to the failure to thrive evident within the skeletal remains of Roman children. Lead concentration and paleopathological analyses were used to explore the association between lead burdens and health during the Roman period. This study includes 173 individuals (66 adults and 107 non-adults) from five sites, AD 1st–4th centuries, located throughout the Roman Empire. Results show a negative correlation between age-at-death and core tooth enamel lead concentrations. Furthermore, higher lead concentrations were observed in children with skeletal evidence of metabolic disease than those without. This study provides the first bioarchaeological evidence that lead poisoning was a contributing factor to the high infant mortality and childhood morbidity rates seen within the Roman world.

KEYWORDS

bioarchaeology, ICP-MS, infant mortality, lead concentrations, tooth enamel

1 | INTRODUCTION

Few historical subjects evoke more fervent debate than what brought about the fall of the Roman Empire. For centuries, scholars have put forth arguments for a plethora of singular causes for its decline, positing everything from the conversion to Christianity, to environmental catastrophe in the wake of a volcanic eruption (Gilfillian, 1990;

Harper, 2017). It is, however, the notion that lead poisoning was a key contributing factor behind its decline that has captured the interest of scholars and general enthusiasts alike. The urban myth-like quality of this theory has ensured its endurance. Historical texts describe a range of maladies associated with lead poisoning, affirming that Roman populations did indeed suffer the deleterious effects of lead toxicity (Lessler, 1988; Needleman, 2009; Retief & Cilliers, 2006;

This is an open access article under the terms of the Creative Commons Attribution License, which permits use, distribution and reproduction in any medium, provided the original work is properly cited.

© 2021 The Authors. *International Journal of Osteoarchaeology* published by John Wiley & Sons Ltd.

Waldron, 1973). Nriagu's (1983) interpretation of the historical literature in terms of the endemicity of lead poisoning and its role in the downfall of the Empire proved particularly influential. The impact of lead poisoning on Roman health and the Empire's ultimate decline, however, is still refuted by many scholars (Cilliers & Retief, 2014; Drasch, 1982; Gaebel, 1983; Needleman & Needleman, 1985; Scarborough, 1984). Although it is unlikely that these debates will ever be fully resolved, the effect that lead had on childhood health and mortality throughout the Empire can be explored directly via skeletal analyses, an immensely important but often under-utilized line of evidence in Roman studies.

Lead is a cumulative poison, and one to which children are particularly susceptible due to the rapid development of their bodies absorbing higher quantities of ingested lead (Hursh & Suomela, 1968; Rabinowitz et al., 1976). Due to the omnipresence of lead within the environment, some ingestion and subsequent accumulation within the body is unavoidable. A diachronic study of childhood lead burdens in British archeological populations (Figure 1) has shown that natural lead concentrations in the tooth enamel of pre-Roman populations rarely exceeded 0.4 ppm (Montgomery et al., 2010). This is below the World Health Organization's recommended blood lead limit of $5 \mu\text{g dL}^{-1}$ (WHO, 2010), equating to an enamel lead concentration of 0.5 ppm (Grobler et al., 2000). Symptoms of metabolic disease begin to manifest with lead concentrations as low as $15 \mu\text{g dL}^{-1}$ and become fatal when levels exceed $140 \mu\text{g dL}^{-1}$ (Bellinger & Bellinger, 2006). In contrast to prehistoric samples, the analysis of Roman dental remains from Britain have revealed enamel lead concentrations equating to blood lead levels over double this fatal limit (Montgomery et al., 2010). However, a recent study by Eshel et al. (2020) highlights in vivo lead pollution in Near Eastern Iron Age individuals (BC 13th–6th centuries), which demonstrates low lead burdens were not ubiquitous in pre-Roman

regions or eras. Notwithstanding, the magnitude with which lead is exploited markedly increases in the Roman Period as revealed through rises in atmospheric lead pollution evidenced in Greenland and Alpine ice cores (McConnell et al., 2018; Preunkert et al., 2019). Further, the decline in this atmospheric pollution coincides with the later Roman Period further solidifying the link between the abundant uses of lead ores with Roman culture.

The dramatic increase in the bioavailability of lead during the Roman period and its general ubiquity due to the widespread and varied use of lead compounds, rendered the Empire's children at an unprecedented risk of exposure (Mackie et al., 1975; Montgomery et al., 2010). Roman children were repeatedly exposed to lead in most aspects of their everyday life through water sources, medicines, utensils, cooking pots, food preservatives and sweeteners, pewter household items, coins, toys, potentially through work-related activities, etc. (Retief & Cilliers, 2006). There is no doubt that childhood was a perilous stage of life during the Roman period, with failure to thrive being an all too common occurrence, evident by high numbers of infant remains in cemeteries and other burial contexts (Carroll, 2014, 2018). Despite this, and modern documentary evidence of lead poisoning being responsible for stillbirths, spontaneous abortion, and deformities in infants (Gilfillian, 1965; Hertz-Picciotto, 2000; Nriagu, 1983; Oliver, 1914; Wibberley et al., 1977; Woolley, 1984), little has been done to explore any link between childhood lead exposure and high infant mortality rates in the Roman Empire. Human skeletal remains provide a rich source of direct information pertaining to the lives and living conditions of past populations (Scott, 2013). This study therefore aims to investigate the degree of lead toxicity in four different regions of the Roman Empire and its impact on childhood health and mortality using paired paleopathological and lead trace element analyses.

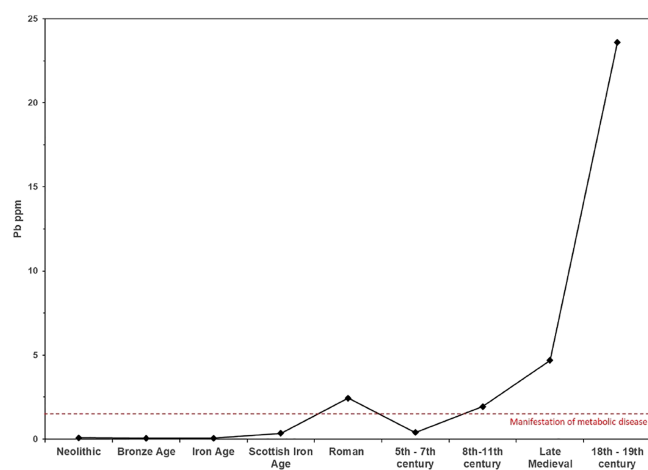


FIGURE 1 Diachronic trends in British human tooth enamel lead concentrations (ppm) from the Neolithic to the 19th century. Adapted from Montgomery et al. (2010), with additional Roman data from Shaw et al. (2016) and 18th–19th century data from Millard et al. (2014). The red dashed line indicates the threshold at which symptoms of lead induced metabolic disease begin to manifest (1.5 ppm) [Colour figure can be viewed at [wileyonlinelibrary.com](https://www.wileyonlinelibrary.com)]

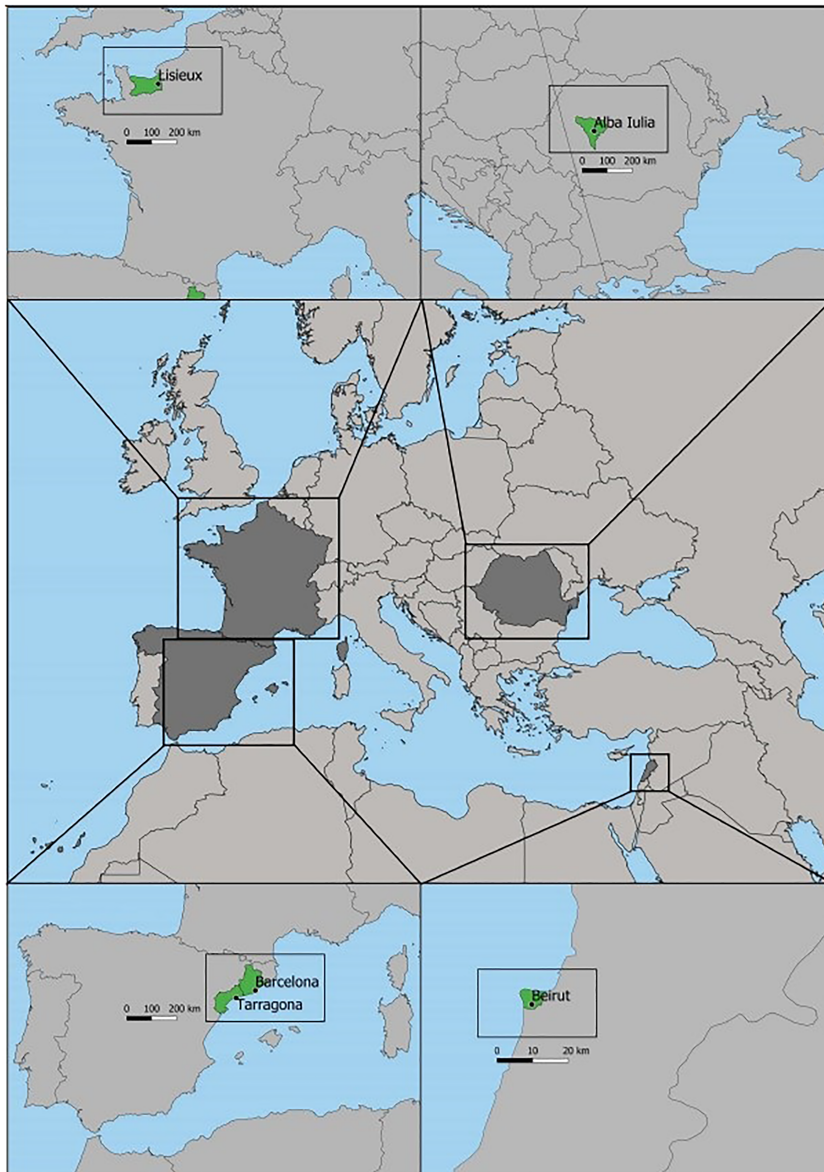
2 | MATERIALS AND METHODS

2.1 | Samples

This study incorporates paleopathological and core tooth enamel lead concentration data from 173 individuals (adults = 66 and non-adults [<18 years] = 107) from five sites of AD 1st to 4th centuries European and Near Eastern from the Roman Empire (see Table 1 and Figure 2). Each of the sites were Roman necropolises located outside the walls of large urban centers. These sites were specifically selected to encompass broad geographical representations of the Empire that are often excluded in Roman studies, as well as for their distance from major lead mining and production centers (e.g., *Britannia*, *Noricum*) in order to mitigate the effects of environmental lead pollution (Aguelo et al., 2001; Arroyo et al., 2005; Gligor et al., 2010; Prast, 2011; Ota, 2009; Paillard & Alduc-Le Bagousse, 2012). The mixed burial rites (simple pits, tegula graves, sarcophagi, and mausolea) and variety of grave goods at each site indicates that the cemeteries included individuals from various socioeconomic strata. The results of the analyses are provided in the supporting information.

TABLE 1 Number of individuals analyzed from each site by age-at-death category

Age category	Site					Total
	Alba Iulia (Romania)	Beirut (Lebanon)	Barcelona (Spain)	Tarragona (Spain)	Lisieux (France)	
Fetal	7	0	1	1	1	10
0–1 year	5	4	3	5	5	22
2–6 years	3	10	8	4	8	33
7–12 years	8	5	6	3	6	28
13–18 years	3	4	4	1	2	14
Adult (18 + years)	11	16	13	12	14	66
Total	37	39	35	26	36	173

**FIGURE 2** Locations of the sites used in this study (drawn by S. Kellett) [Colour figure can be viewed at wileyonlinelibrary.com]

2.2 | Osteological analyses

Adult sex was determined using the sexually dimorphic traits of the pelvis and skull as described by Phenice (1969), Ferembach

et al. (1979), and Walker (2005). Following standard practice (e.g., Buikstra & Ubelaker, 1994), sex assessment was not attempted for the non-adult individuals, all of which were categorized as indeterminate.

Non-adults were categorized as those aged less than 18 years, assessed using dental development (AlQahtani et al., 2010), long bone length (Scheuer et al., 1980; Scheuer & Black, 2000) and epiphyseal fusion (Scheuer & Black, 2000). Adult age was estimated using morphological changes in the pubic symphysis (Brooks & Suchey, 1990), the auricular surface (Buckberry & Chamberlain, 2002; Lovejoy et al., 1985), cranial suture closure (Meindl & Lovejoy, 1985), and dental wear (Brothwell, 1981).

2.3 | Paleopathological analyses

Lead is an insidious poison and the gradual accumulation of the metal in bodily tissues becomes increasingly toxic. Due to the systemic nature of lead poisoning, the clinical manifestations of toxicity are varied and complex. With the exception of lead lines visible at the growing ends of bones (metaphyses) on radiographs, no specific skeletal lesions have been associated with lead poisoning (Rabinowitz

et al., 1993). This is most likely due to the toxicodynamics of absorbed lead culminating in clinical manifestations that are common to many other disease processes. However, with its propensity to disrupt metabolic pathways, it is unsurprising that both modern and historical clinical literature associate lead poisoning with a number of metabolic diseases, such as rickets, scurvy and anemia (Rabinowitz et al., 1993; Caffey, 1938; Waldron, 1966; Smith et al., 1938). Therefore, it is probable that individuals who died suffering the ill effects of chronic lead poisoning would exhibit pathological skeletal alterations consistent with these metabolic diseases.

Paleopathological analysis of the non-adult individuals focused on the identification of metabolic diseases associated in the clinical literature with lead poisoning (Landrigan, 1989; Landrigan & Todd, 1994). The following section outlines the paleopathological features of the metabolic stress often associated with lead poisoning and the parameters used to diagnose these diseases within the skeletal assemblages. No radiographs were available for any of the study sites; therefore, diagnoses were made solely from macroscopic examination of

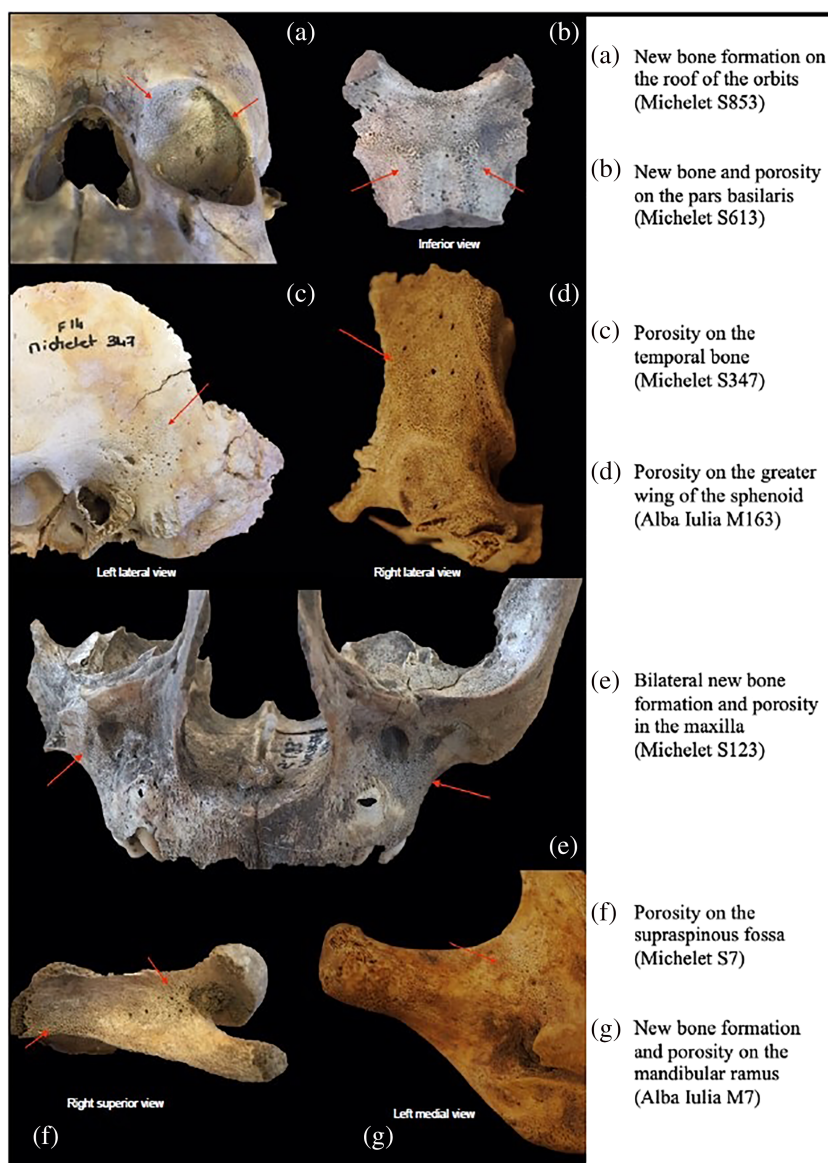


FIGURE 3 Non-adult skeletal elements exhibiting areas of abnormal cortical porosity and subperiosteal new bone formation consistent with metabolic disease [Colour figure can be viewed at wileyonlinelibrary.com]

individuals with observable elements. Examples of the skeletal manifestation of these metabolic diseases are presented in Figure 3.

2.3.1 | Rickets

Rickets is generally identified by bowing of the long bones and/or the presence of widened, cupped and porous/frayed (“brush end”) epiphyses, sternal rib-end flaring (“rachitic rosary”) and cranial vault thinning (Waldron, 2009, p. 129). Additional manifestations of the disease in non-adults can also include orbital roof porosity, deformation of the mandibular ramus, porosity of the sternal rib-ends and deformation of the ribs (Brickley et al., 2005; Brickley & Ives, 2010; Mays et al., 2006; Ortner, 2003; Ortner & Mays, 1998). Using the published diagnostic criteria outlined in Table 2, macroscopic lesions were recorded as either present or absent. Because many of the lesions associated with rickets can have multiple etiologies (Mays et al., 2006; Ortner & Mays, 1998), a diagnosis of rickets was only recorded if three or more probable rachitic features were present, or if there were bending deformities of the long bones plus one other feature. This was done to avoid over diagnoses of rickets in the sample population. Individuals exhibiting no probable features but three or more possible features alongside any non-diagnostic features were considered as possibly rachitic. Using Ortner and Mays (1998) definition, a distinction was also made between healed and active rickets.

2.3.2 | Scurvy

Pathological alterations indicative of scurvy primarily consist of abnormal cortical porosity (often with subperiosteal new bone formation) on the ectocranial surface, scapulae, long bone metaphyses, and

mandible (Schattmann et al., 2016; Snoddy et al., 2018; Stark, 2014). These lesions tend to manifest bilaterally and are thought to be caused by chronic, low-grade hemorrhage of weakened blood vessels, predominantly at muscle attachment sites, which stimulates an inflammatory response (Ortner et al., 1999, 2001; Ortner & Ericksen, 1997). Although abnormal cortical porosity is the primary lesion associated with scurvy, it is also common to many other disease processes such as specific and non-specific infection, hemoglobinopathies, anemias, and other metabolic disorders (Brown & Ortner, 2011; Lagia et al., 2007). It is therefore important to analyze the porosity in relation to its distribution across the entire skeleton. Using the published diagnostic criteria outlined in Table 3, macroscopic lesions were recorded as either present or absent. In line with recommendations by Snoddy et al. (2018), individuals were recorded as scorbutic if two or more diagnostic scorbutic features were present. If the individual revealed multiple suggestive features, they were considered as possibly scorbutic.

2.3.3 | Cribra orbitalia and porotic hyperostosis

Cribra orbitalia was identified as porotic changes of the orbital roofs and recorded for each orbit using the Stuart-Macadam (1991) grading system. Any individual with cribrotic lesions over the age of 10 was designated as having the healed form of cribra orbitalia due to the red-to-yellow marrow conversion that occurs around this age, thereby precluding the formation of these lesions (Simonson & Kao, 1992). Porotic hyperostosis was identified as abnormal cortical porosity of the cranial vault, and recorded as either present or absent (Mann & Hunt, 2013, p. 28; Waldron, 2009, p. 137). Cross-sections of parietal bones that showed abnormal widening/thickening of the diploic space was also noted as potential marrow hyperplasia (thickening) of the cranial vault.

TABLE 2 Rachitic lesions used in the identification of rickets and their diagnostic category

Diagnostic category	Probable	Possible	Non-diagnostic
Cranial	Deformed mandibular ramus	Cranial vault porosity	Delayed closure of fontanelles
		Orbital roof porosity	Cranial bone thinning
		Layers of speculated, irregular porous bone can occur during healing when osteoid is mineralising	Frontal and parietal bossing
			Craniotabes (softening of bone behind ears over occipital region and adjacent to lambdoid suture)
			Formation of large, square shaped head
Post-cranial	Deformed arm bones Deformed leg bones Ilium concavity Altered rib angle	Flaring of sternal rib-ends	Superior flattening of the femora
		Porosity of sternal rib-ends	
		Long bone metaphyseal flaring	
		Long bone thickening	
		Porous roughening of long bone metaphyses Long bone concave curvature porosity	

Note: After Brickley and Ives (2010), Hess (1930), Mays et al. (2006), Ortner and Mays (1998), and Pettifor (2011).

TABLE 3 Scorbutic lesions used in the identification of scurvy and their diagnostic category

Diagnostic category	Probable	Possible	Non-diagnostic
Cranial	Porosity and/or new bone formation on the greater wing of the sphenoid Porosity on the posterior aspect of the mandible Porosity on the temporal bone	Porosity in the mandibular coronoid fossae Porosity and/or new bone formation on the lesser wing of the sphenoid Porosity at the infraorbital foramen on the maxilla Porosity and/or new bone formation on the orbital roof Porosity and/or new bone formation on the pars basilaris	Porosity on the palate of the maxilla Porosity in the maxilla and/or mandibular alveola processes Porosity and/or new bone formation on the endocranium
Post-cranial	Porosity and/or new bone formation in the supraspinous and/or infraspinous fossae	Metaphyseal flaring of long bones Flaring of sternal rib-ends	Porosity and/or new bone formation on the long bones Metaphyseal porosity

Note: After Brickley and Ives (2006, 2010), Geber and Murphy (2012), Moore and Koon (2017), Ortner (2003), Ortner et al. (1999, 2001), and Ortner and Erickson (1997).

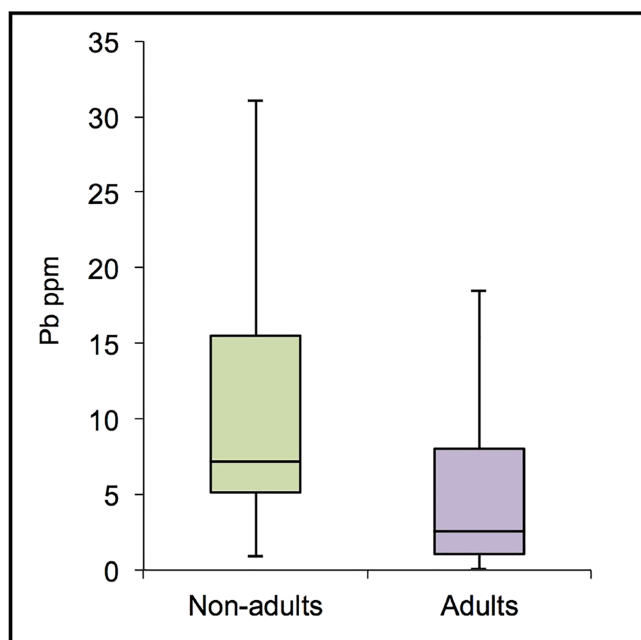


FIGURE 4 Box and whisker plot comparing core tooth enamel lead concentrations (ppm) from adult ($n = 66$) and non-adult ($n = 107$) Roman individuals [Colour figure can be viewed at wileyonlinelibrary.com]

2.4 | Lead concentration analysis

Initial sample preparation was carried out at the Archaeological Isotope and Peptide Laboratory (AIPRL), Durham University, following procedures outlined by Montgomery (2002), briefly described here: The enamel surface was abraded using a tungsten carbide dental bur to remove surface contamination. Following this, a chip of enamel was removed using a flexible diamond edged rotary saw, all exposed surfaces of the chip were abraded to remove any adhering dentine and potential sources of contamination. Enamel chips were stored

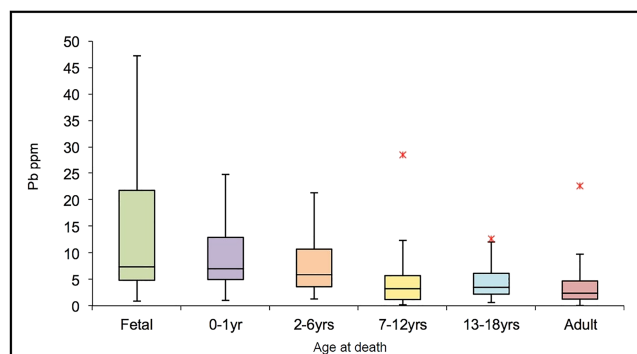


FIGURE 5 Box and whisker plot comparing core tooth enamel lead concentrations (ppm) with age-at-death ($n = 173$) [Colour figure can be viewed at wileyonlinelibrary.com]

in clean micro-centrifuge tubes for transfer to the National Environmental Isotope Facility (NEIF), British Geological Survey, Keyworth. All dental tools were cleaned between samples via ultra-sonication in Decon for 5 min and rinsed three times with ultra-pure de-ionized water.

Trace element analysis was carried out at NEIF using an Agilent 7500cx ICP-MS fitted with a CETAC ASX-520 autosampler. Sample introduction from the autosampler to the Inductively Coupled Plasma Mass Spectrometry (ICP-MS) was controlled by a CETAC ASXpress + vacuum pump. Multi-element quality control (QC) check standards, containing the trace elements of interest at $25 \mu\text{g L}^{-1}$, and a separate major element QC were analyzed at the start and end of each run and after no more than every 20 samples. To overcome polyatomic interferences the ICP-MS collision cell was operated in He mode at a flow rate of 5.5 mL min^{-1} for all analytes except Se, for which H_2 gas was used at 4.5 mL min^{-1} due to the more intense interferences experienced with Se because of argon (Ar) dimers formed in the plasma. Samples were diluted with 1% v/v HNO_3 . 0.5% v/v HCl before analysis. Quantitative data analysis was carried out using MassHunter Workstation software (Agilent).

3 | RESULTS AND DISCUSSION

Lead is incorporated into the mineral matrix of tooth enamel during childhood and does not alter *in vivo* or undergo diagenetic changes from the burial environment after the tissue mineralises; therefore, lead concentrations acquired in this way represent an individual's childhood exposure to the toxic metal (Montgomery et al., 2010). Early studies show that deciduous tooth enamel often has higher lead concentrations than permanent tooth enamel, and this is thought to

be because younger children absorb higher quantities of lead relative to older children with similar exposure (Shapiro et al., 1972). If age-related absorption rates led to higher lead concentrations in deciduous teeth, regardless of exposure level, then co-forming permanent teeth would be expected to yield similarly high lead concentrations. However, a recent study shows no significant difference in median tooth enamel lead concentration between earlier and later permanent tooth types (e.g., second and third molars) (Moore, 2019). This suggests that age-related lead absorption rates are not the dominant

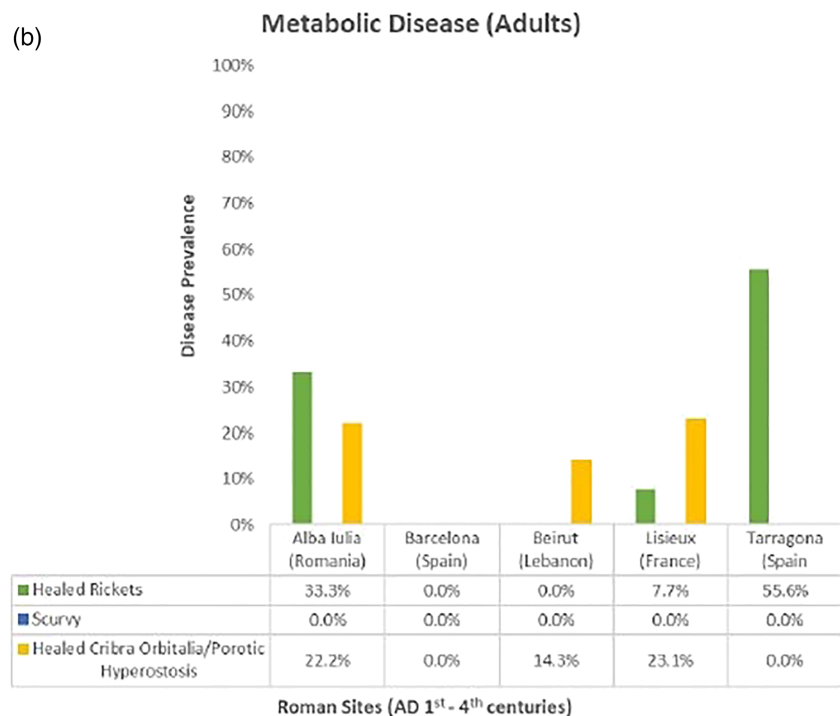
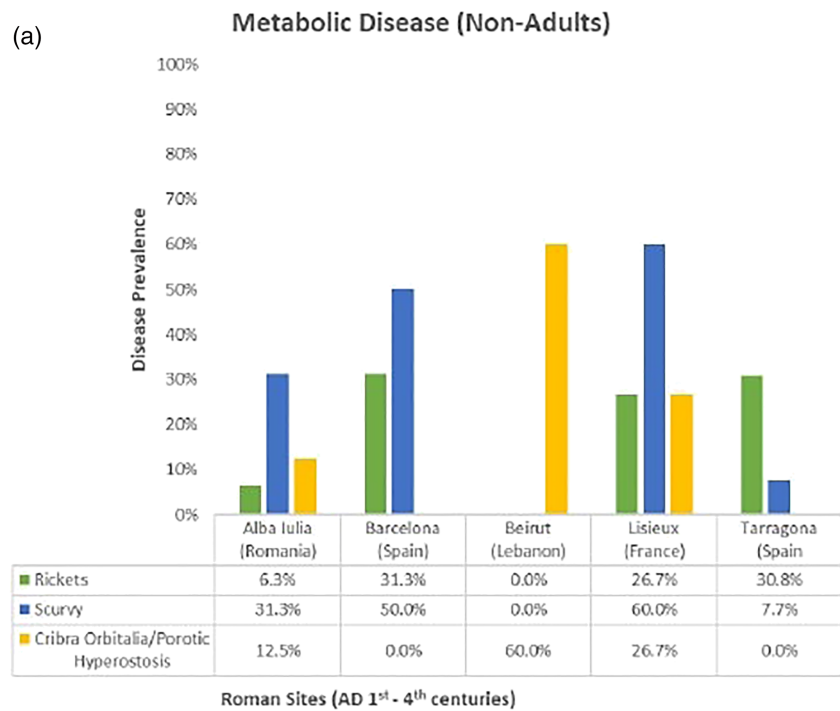


FIGURE 6 Prevalence of metabolic diseases in the observable (a) non-adult ($n = 65$) and (b) adult ($n = 51$) sample populations [Colour figure can be viewed at [wileyonlinelibrary.com](https://onlinelibrary.com)]

factor influencing lead concentrations in tooth enamel, and that comparing lead concentrations in deciduous and permanent tooth enamel provides a useful means of investigating the effects of lead exposure on childhood health (*ibid*). In this study a comparison of the lead concentration data from the adult and non-adult individuals show that those who survived into adulthood had lower childhood lead burdens (median = 2.6 ppm) than those who died during childhood (median = 7.2 ppm) (see Figure 4). The results of a Kruskal–Wallis test showed that the median lead concentrations in these two groups were statistically significantly different ($X^2 = 12.181$, $p = 0.0005$). Children have more than double the lead concentrations observed in adults, suggesting that higher lead burdens are accompanied by lower life expectancies. These results offer the first bioarcheological evidence that lead poisoning resulted in increased frailty for citizens of the Roman Empire.

It is evident from the archeological record that there is a real failure to thrive in children throughout the Roman period (Carroll, 2014; Rohnbogner, 2017; Rohnbogner & Lewis, 2017). It is estimated that up to 50% of children died before the age of 10 years old, with 20–40% of these not reaching the age of 1 year (Carroll, 2014, 2018). Children are more susceptible to lead poisoning than adults as their developing bodies are prone to absorbing higher quantities of ingested lead. To explore whether the high lead burdens characteristic of Roman individuals contributed to the high childhood mortality rates in the Roman Empire, lead concentrations were further compared to age-at-death (see Figure 5). A negative correlation between lead concentration and age-at-death is evident, again indicating that individuals with lower lead burdens lived longer than those with higher lead burdens. This is particularly interesting with regards to children under the age of 1 year. Explanations for high infant mortality rates during the Roman period have ranged from malnutrition and disease to infanticide and exposure (Gowland et al., 2014; Mays, 1993; Pilkington, 2013; Rohnbogner, 2017). The results of this study offer new insights into the previously overlooked role that lead may have played in these high infant mortality rates. Unfortunately, little research has been done to understand how lead concentrations in tooth enamel reflect *in vivo* lead burdens, or how they correlate to manifestations of lead poisoning during life (Grobler et al., 2000; Rabinowitz et al., 1993). As such, identifying high lead concentrations in archeological remains alone is unlikely to be sufficient to determine those who may have died from lead poisoning. However, using modern clinical literature and the known biochemical pathogenesis of lead toxicity it may be possible to further elucidate the effect of lead poisoning on the health of archeological populations.

Of the sample population, 65/107 non-adults and 51/66 adults demonstrated suitable preservation for paleopathological evaluation. Results indicate that 46/65 (71%) non-adults with observable elements exhibit pathological lesions diagnostic or consistent with rickets, scurvy, and/or cribra orbitalia and porotic hyperostosis (see Figure 6, S1). This is considerably lower when compared to the adult “survivor” population, of which 15/51 (29%) demonstrate lesions consistent with these metabolic diseases.

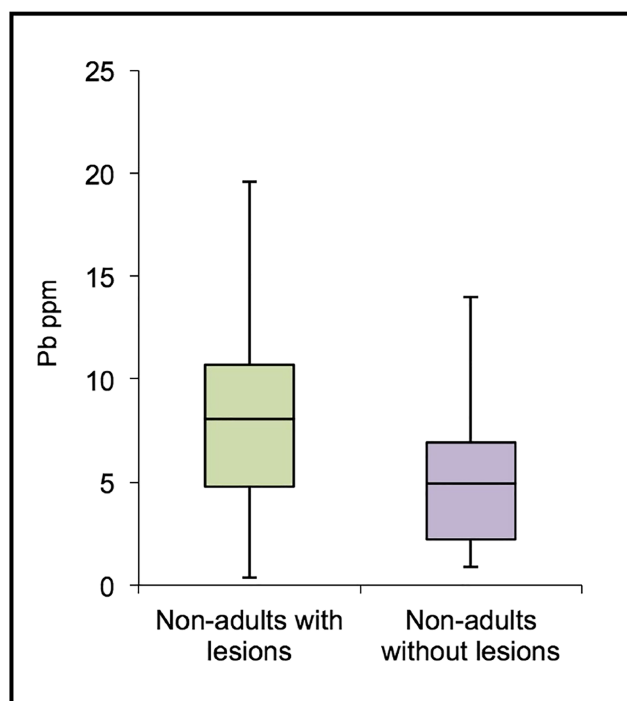


FIGURE 7 Box and whisker plot comparing core tooth enamel lead concentrations (ppm) from non-adults with pathological lesions consistent with metabolic disease ($n = 46$) and non-adults with no skeletal evidence of metabolic disease ($n = 31$) [Colour figure can be viewed at wileyonlinelibrary.com]

The non-adult individuals exhibiting pathological lesions diagnostic of metabolic disease had significantly higher lead concentrations (median = 8.1 ppm) than those without (median = 4.9 ppm) (see Figure 7). A Kruskal–Wallis test showed a statistically significant difference in lead concentrations between these two groups ($X^2 = 4.007$, $p = 0.0453$). While these metabolic diseases have multiple etiologies, the association with lead supports the presupposition that high lead concentrations are also implicated in Roman-period skeletons. Thus, elevated levels of environmental lead pollution characteristic of the Roman period did have a negative impact upon childhood health. In future, it is worth exploring if differences in lead concentrations exist chronologically (i.e., earlier vs. later Roman contexts), examining the extent to which geographical differences influence childhood lead burdens, and exploring how lead isotope ratios vary between different regions to better understand mobility and trade networks within the Empire.

4 | CONCLUSION

Through the combination of paleopathological and trace element analyses, lead poisoning can tentatively be identified in archeological human remains. The results of this study demonstrate that increased exposure to anthropogenically produced lead was a contributing factor to the ill health and failure to thrive seen in many Roman

infants and children, thereby providing the first bioarcheological evidence that lead poisoning may have been a contributing factor to the high infant mortality rates seen in Roman skeletal populations. The introduction of a bioarcheological perspective to the decades old debate regarding the impact of lead on Roman health offers new insights into the effects of environmental lead pollution on child health during this period.

ACKNOWLEDGMENTS

The authors are grateful to the Museu Nacional Arqueològica de Tarragona (MNAT), Museu d'Història de Barcelona (MUHBA), Universitat de Caen, Universitat "1 Decembre 1918" Alba Iulia, the Lebanese Ministry of Culture, and Lebanese Directorate General of Antiquities (with special thanks to Drs. Assaad Seif and Georges Abou Diwan) for access to skeletal material and site information. Simon Chenery (NIGL/BGS) is thanked for his support and assistance in processing the trace element analysis, and the authors thank Sal Kellett (Durham University) for producing Figure 2. Funding to J. Moore under NERC IAPETUS studentship NE/L002590/1 supported this research.

CONFLICT OF INTEREST

The authors declare that they have no conflict of interest.

ORCID

Joanna Moore  <https://orcid.org/0000-0003-3918-4583>

Kori Filipek  <https://orcid.org/0000-0002-7058-2216>

Vana Kalenderian  <https://orcid.org/0000-0002-7952-9243>

REFERENCES

- Aguelo, J., Huertas, J., & Puig, F. (2001). Les excavacions a l'antic convent de Santa Caterina de Barcelona (Barcelonès). *Tribuna d'Arqueologia*, 2002, 208–224.
- AlQahtani, S., Hector, M., & Liversidge, H. (2010). Brief communication: The London atlas of human tooth development and eruption. *American Journal of Physical Anthropology*, 142, 481–490. <https://doi.org/10.1002/ajpa.21258>
- Arroyo, J. H., i Verdaguier, F. P., & Mas, J. A. (2005). Santa Caterina de Barcelona: Assaig d'ocupació i evolució. *Quarhis: Quaderns d'Arqueologia i Història de la Ciutat de Barcelona*, 11–43.
- Bellinger, D. C., & Bellinger, A. M. (2006). Childhood lead poisoning: The torturous path from science to policy. *The Journal of Clinical Investigation*, 116(4), 853–857. <https://doi.org/10.1172/JCI28232>
- Brickley, M., & Ives, R. (2006). Skeletal manifestations of infantile scurvy. *American Journal of Physical Anthropology*, 129, 163–172. <https://doi.org/10.1002/ajpa.20265>
- Brickley, M., & Ives, R. (2010). *The bioarchaeology of metabolic bone disease* (p. 20). London, UK: Elsevier Academic Press.
- Brickley, M., Mays, S., & Ives, R. (2005). Skeletal manifestations of vitamin D deficiency osteomalacia in documented historical collections. *International Journal of Osteoarchaeology*, 15, 389–403. <https://doi.org/10.1002/oa.794>
- Brooks, S., & Suchey, J. M. (1990). Skeletal age determination based on the os pubis: A comparison of the Acsádi-Nemeskéri and Suchey-Brooks methods. *Human Evolution*, 5(3), 227–238. <https://doi.org/10.1007/BF02437238>
- Brothwell, D. R. (1981). *Digging up bones*. Ithaca, NY: Cornell University Publishing.
- Brown, M., & Ortner, D. J. (2011). Childhood scurvy in a medieval burial from Mačvanska Mitrovica, Serbia. *International Journal of Osteoarchaeology*, 21, 197–207. <https://doi.org/10.1002/oa.1124>
- Buckberry, J. L., & Chamberlain, A. T. (2002). Age estimation from the auricular surface of the ilium: A revised method. *American Journal of Physical Anthropology*, 119(3), 231–239. <https://doi.org/10.1002/ajpa.10130>
- Buikstra, J. E., & Ubelaker, D. H. (1994). *Standards for Data Collection from Human Remains*. Arkansas Archaeological Survey Research.
- Caffey, J. (1938). Lead poisoning associated with active rickets: Report of a case with absence of lead lines in the skeleton. *American Journal of Diseases of Children*, 55(4), 798–806. <https://doi.org/10.1001/archpedi.1938.01980100134010>
- Carroll, M. (2014). Mother and infant in Roman funerary commemoration. In M. Carroll & E.-J. Graham (Eds.), *Infant health and death in Roman Italy and beyond* (pp. 159–178). Portsmouth, RI, USA: Journal of Roman Archaeology.
- Carroll, M. (2018). *Infancy and earliest childhood in the Roman world: 'A fragment of time'*. Oxford University Press.
- Cilliers, L., & Retief, F. (2014). Lead poisoning and the downfall of Rome: Reality or myth? *History of Toxicology and Environmental Health*, 118.
- Drasch, G. A. (1982). Lead burden in prehistorical, historical and modern human bones. *Science of the Total Environment*, 24(3), 199–231. [https://doi.org/10.1016/0048-9697\(82\)90001-8](https://doi.org/10.1016/0048-9697(82)90001-8)
- Eshel, T., Yahalom-Mack, N., Tirosh, O., Maeir, A. M., Harlavan, Y., Gilboa, A., & Erel, Y. (2020). Pollution and human mobility in the southern Levant during the Iron age using chemical and isotopic analysis of human tooth enamel. *Journal of Archaeological Science*, 124, 105262. <https://doi.org/10.1016/j.jas.2020.105262>
- Ferembach, D., Schwidetzky, I., & Stloukal, M. (1979). Recommendations for age and sex diagnoses of skeletons. *Bulletins Et Memoires De La Societe D Anthropologie De Paris*, 6, 7–45. <https://doi.org/10.3406/bmsap.1979.1945>
- Gaebel, R. E. (1983). Saturnine gout among Roman aristocrats. *The New England Journal of Medicine*, 309(7), 431.
- Geber, J., & Murphy, E. (2012). Scurvy in the Great Irish Famine: Evidence of vitamin C deficiency from a mid-19th century skeletal population. *American Journal of Physical Anthropology*, 148(4), 512–524.
- Gilfillian, S. C. (1965). Lead poisoning and the fall of Rome. *Journal of Occupational Medicine*, 7(2), 53–60.
- Gilfillian, S. C. (1990). *Rome's ruin by lead poisoning*. Long Beach, CA: Wenzel Press.
- Gligor, M., Bogdan, D., Mazare, P., Lipot, Ş., & Balteş, G. (2010). Morminte romane din necropola de pe Dealul Furcilor de la Apulum. *Terra Sebus*, 2, 117–139.
- Gowland, R. L., Chamberlain, A., & Redfern, R. C. (2014). On the brink of being: Re-evaluating infanticide and infant burial in Roman Britain. *Journal of Roman Archaeology Supplementary Series*, 96, 69–88.
- Grobler, S. R., Theunissen, F. S., & Kotze, T. J. (2000). The relation between lead concentrations in human dental tissues and in blood. *Archives of Oral Biology*, 45, 607–609. [https://doi.org/10.1016/S0003-9969\(00\)00024-8](https://doi.org/10.1016/S0003-9969(00)00024-8)
- Harper, K. (2017). The fate of Rome: Climate, disease, and the end of an empire (the Princeton history of the ancient world), DOI: <https://doi.org/10.2307/j.ctv9b2txr>
- Hertz-Picciotto, I. (2000). The evidence that lead increases the risk for spontaneous abortion. *American Journal of Industrial Medicine*, 38(3), 300–309. [https://doi.org/10.1002/1097-0274\(200009\)38:3<300::AID-AJIM9>3.0.CO;2-C](https://doi.org/10.1002/1097-0274(200009)38:3<300::AID-AJIM9>3.0.CO;2-C)
- Hess, A. F. (1930). *Rickets including osteomalacia and tetany* (Vol. 23) (p. 474). London: Henty Kimpton. <https://doi.org/10.1097/00007611-193005000-00040>
- Hursh, J. B., & Suomela, J. (1968). Absorption of ²¹²Pb from the gastrointestinal tract of man. *Acta Radiologica: Therapy, Physics, Biology*, 7(2), 108–120.

- i Prast, J. C. (2011). Pràctiques i rituals funeraris a Tàrraco i el seu ager (segles II ac-III/IV dc).
- Lagia, A., Eliopoulos, C., & Manolis, S. (2007). Thalassemia: Macroscopic and radiological study of a case. *International Journal of Osteoarchaeology*, 17, 269–285. <https://doi.org/10.1002/oa.881>
- Landrigan, P. (1989). Toxicity of lead at low dose. *British Journal of Industrial Medicine*, 46, 593–596.
- Landrigan, P. J., & Todd, A. C. (1994). Lead poisoning. *The Western Journal of Medicine*, 161, 153–159.
- Lessler, M. A. (1988). Lead and lead poisoning from antiquity to modern times. *The Ohio Journal of Science*, 88(3), 78–84.
- Lovejoy, C. O., Meindl, R. S., Pryzbeck, T. R., & Mensforth, R. P. (1985). Chronological metamorphosis of the auricular surface of the ilium: A new method for the determination of adult skeletal age at death. *American Journal of Physical Anthropology*, 68(1), 15–28. <https://doi.org/10.1002/ajpa.1330680103>
- Mackie, A., Townshend, A., & Waldron, H. A. (1975). Lead concentrations in bones from Roman York. *Journal of Archaeological Science*, 2, 235–237. [https://doi.org/10.1016/0305-4403\(75\)90062-X](https://doi.org/10.1016/0305-4403(75)90062-X)
- Mann, R. W., & Hunt, D. R. (2013). *Photographic regional atlas of bone disease: A guide to pathologic and normal variation in the human skeleton*. Springfield: Charles C Thomas Publisher Ltd.
- Mays, S. (1993). Infanticide in Roman Britain. *Antiquity*, 67(257), 883–888. <https://doi.org/10.1017/S0003598X00063900>
- Mays, S., Brickley, M., & Ives, R. (2006). Skeletal manifestations of rickets in infants and young children in a historic population from England. *American Journal of Physical Anthropology*, 129, 362–374. <https://doi.org/10.1002/ajpa.20292>
- McConnell, J. R., Wilson, A. I., Stohl, A., Arienzo, M. M., Chellman, N. J., Eckhardt, S., Thompson, E. M., Pollard, A. M., & Steffensen, J. P. (2018). Lead pollution recorded in Greenland ice indicates European emissions tracked plagues, wars, and imperial expansion during antiquity. *Proceedings of the National Academy of Sciences*, 115(22), 5726–5731. <https://doi.org/10.1073/pnas.1721818115>
- Meindl, R. S., & Lovejoy, C. O. (1985). Ectocranial suture closure: A revised method for the determination of skeletal age at death based on the lateral-anterior sutures. *American Journal of Physical Anthropology*, 68(1), 57–66. <https://doi.org/10.1002/ajpa.1330680106>
- Millard, A., Montgomery, J., Trickett, M., Beaumont, J., Evans, J., & Chenery, S. (2014). Childhood lead exposure in the British Isles during the industrial revolution. In M. K. Zuckermann (Ed.), *Modern environments and human health: Revisiting the second epidemiological transition* (pp. 269–289). Wiley.
- Montgomery, J. (2002). Lead and strontium isotope compositions of human dental tissues as an indicator of ancient exposure and population dynamics. University of Bradford, PhD thesis.
- Montgomery, J., Evans, J. A., Chenery, S. A., Pashley, V., & Killgrove, K. (2010). Gleaming, white and deadly: Using lead to track human exposure and geographic origins in the Roman period of Britain. *Journal of Roman archaeology; supplementary series*, 78, 199–226.
- Moore, J. (2019). Death metal: Characterising the effects of environmental lead pollution on childhood health and mobility within the Roman Empire. Durham University. PhD thesis.
- Moore, J., & Koon, H. E. C. (2017). Basilar portion porosity: A pathological lesion possibly associated with infantile scurvy. *International Journal of Paleopathology*, 18, 92–97. <https://doi.org/10.1016/j.ijpp.2017.05.010>
- Needleman, H. L. (2009). Low level lead exposure: History and discovery. *Annals of Epidemiology*, 19(4), 235–238. <https://doi.org/10.1016/j.annepidem.2009.01.022>
- Needleman, L., & Needleman, D. (1985). Lead poisoning and the decline of the Roman aristocracy. *Classical Views*, 4(1), 64–94.
- Nriagu, J. O. (1983). Lead, lore and early theories of lead materiality. In J. O. Nriagu (Ed.), *Lead and Lead poisoning in antiquity* (pp. 1–65). New York, NY, USA: Wiley and Sons.
- Oliver, T. (1914). Lead poisoning: From the industrial, medical and social points of view (London).
- Ortner, D. J. (2003). *Identification of pathological conditions in human skeletal remains* (2nd ed.) (p. 22). London, UK: Academic Press.
- Ortner, D. J., Butler, W., Cafarella, J., & Milligan, L. (2001). Evidence of probable scurvy in subadults from archeological sites in North America. *American Journal of Physical Anthropology*, 114, 343–351. <https://doi.org/10.1002/ajpa.1046>
- Ortner, D. J., & Ericksen, M. F. (1997). Bone changes in the human skull probably resulting from scurvy in infancy and childhood. *International Journal of Osteoarchaeology*, 7, 212–220. [https://doi.org/10.1002/\(SICI\)1099-1212\(199705\)7:3<212::AID-OA346>3.0.CO;2-5](https://doi.org/10.1002/(SICI)1099-1212(199705)7:3<212::AID-OA346>3.0.CO;2-5)
- Ortner, D. J., Kimmerle, E. H., & Diez, M. (1999). Probable evidence of scurvy in subadults from archeological sites in Peru. *American Journal of Physical Anthropology*, 108, 321–331. [https://doi.org/10.1002/\(SICI\)1096-8644\(199903\)108:3<321::AID-AJPA7>3.0.CO;2-7](https://doi.org/10.1002/(SICI)1096-8644(199903)108:3<321::AID-AJPA7>3.0.CO;2-7)
- Ortner, D. J., & Mays, S. (1998). Dry-bone manifestations of rickets in infancy and early childhood. *International Journal of Osteoarchaeology*, 8(45–55), 26.
- Ota, R. (2009). Some observations on the latest archaeological researches carried out in the Roman necropolis from Apulum (Alba Iulia)-“Dealul Furcilor-Podeii”. *Ephemeris Napocensis*, 19, 23–49.
- Paillard, D., & Alduc-Le Bagousse, A. (2012). La nécropole Michelet à Lisieux (Calvados) Genèse et évolution d'une cité des origines au IXe siècle. Unpublished site report.
- Pettifor, J. M. (2011). Vitamin D deficiency and nutritional rickets in children. In *Vitamin D* (third ed.) (pp. 1107–1128). Elsevier.
- Phenice, T. (1969). A newly developed visual method of sexing the Os pubis. *American Journal of Physical Anthropology*, 30, 297–301. <https://doi.org/10.1002/ajpa.1330300214>
- Pilkington, N. (2013). Growing up Roman: Infant mortality and reproductive development. *The Journal of Interdisciplinary History*, 44(1), 1–36. https://doi.org/10.1162/JINH_a_00499
- Preunkert, S., McConnell, J. R., Hoffmann, H., Legrand, M., Wilson, A. I., Eckhardt, S., Stohl, A., Chellman, N. J., Arienzo, M. M., & Friedrich, R. (2019). Lead and antimony in basal ice from Col du Dome (French Alps) dated with radiocarbon: A record of pollution during antiquity. *Geophysical Research Letters*, 46(9), 4953–4961. <https://doi.org/10.1029/2019GL082641>
- Rabinowitz, M. B., Leviton, A., & Bellinger, D. (1993). Relationships between serial blood lead levels and exfoliated tooth dentin lead levels: Models of tooth lead kinetics. *Calcified Tissue International*, 53, 338–341. <https://doi.org/10.1007/BF01351840>
- Rabinowitz, M. B., Wetherill, G. W., & Kopple, J. D. (1976). Kinetic analysis of lead metabolism in healthy humans. *The Journal of Clinical Investigation*, 58(2), 260–270. <https://doi.org/10.1172/JCI108467>
- Retief, F. P., & Cilliers, L. (2006). Lead poisoning in ancient Rome. *Acta Theologica*, 26(2), 147–164.
- Rohnbogner, A. (2017). Listening to the kids: The value of childhood palaeopathology for the study of rural Roman Britain. *Britannia*, 48, 221–252. <https://doi.org/10.1017/S0068113X17000149>
- Rohnbogner, A., & Lewis, M. E. (2017). Poundbury camp in context—A new perspective on the lives of children from urban and rural Roman England. *American Journal of Physical Anthropology*, 162(2), 208–228. <https://doi.org/10.1002/ajpa.23106>
- Scarborough, J. (1984). The myth of lead poisoning among romans: An essay reviewed. *Journal of the History of Medicine and Allied Sciences*, 39(4), 469–475. <https://doi.org/10.1093/jhmas/39.4.469>
- Schattmann, A., Bertrand, B., Vatteoni, S., & Brickley, M. (2016). Approaches to co-occurrence: Scurvy and rickets in infants and young children of 16–18th century Douai, France. *International Journal of Paleopathology*, 12, 63–75. <https://doi.org/10.1016/j.ijpp.2015.12.002>
- Scheuer, J. L., Musgrave, J. H., & Evans, S. P. (1980). The estimation of late fetal and perinatal age from limb bone length by linear and logarithmic

- regression. *Annals of Human Biology*, 7, 257–265. <https://doi.org/10.1080/03014468000004301>
- Scheuer, L., & Black, S. (2000). *Developmental juvenile osteology*. London: Elsevier Academic Press.
- Scott, G. (2013). Curating human remains in a regional museum: Policy and practice at the Great North Museum: Hancock. In M. Giesen (Ed.), *Curating human remains: Caring for the dead in the United Kingdom* (pp. 99–108). Woodbridge, UK: The Boydell Press.
- Shapiro, I. M., Needleman, H. L., & Tuncay, O. C. (1972). The lead content of human deciduous and permanent teeth. *Environmental Research*, 5, 467–470.
- Shaw, H., Montgomery, J., Redfern, R., Gowland, R., & Evans, J. (2016). Identifying migrants in Roman London using lead and strontium stable isotopes. *Journal of Archaeological Science*, 66, 57–68. <https://doi.org/10.1016/j.jas.2015.12.001>
- Simonson, T. M., & Kao, S. C. S. (1992). Normal childhood developmental patterns in skull bone marrow by MR imaging. *Pediatric Radiology*, 22(8), 556–559. <https://doi.org/10.1007/BF02015347>
- Smith, F. L., Rathmell, T. K., & Marcil, G. E. (1938). The early diagnosis of acute and latent plumbism. *American Journal of Clinical Pathology*, 8(5), 471–508. <https://doi.org/10.1093/ajcp/8.5.471>
- Snoddy, A. M. E., Buckley, H. R., Elliott, G. E., Standen, V. G., Arriaza, B. T., & Halcrow, S. E. (2018). Macroscopic features of scurvy in human skeletal remains: A literature synthesis and diagnostic guide. *American Journal of Physical Anthropology*, 167(4), 876–895. <https://doi.org/10.1002/ajpa.23699>
- Stark, R. J. (2014). A proposed framework for the study of paleopathological cases of subadult scurvy. *Int. J. Paleopathol.*, 5, 18–26. <https://doi.org/10.1016/j.ijpp.2014.01.005>
- Waldron, H. A. (1966). The anaemia of lead poisoning: A review. *British Journal of Industrial Medicine*, 23(2), 83–100. <https://doi.org/10.1136/oem.23.2.83>
- Waldron, H. A. (1973). Lead poisoning in the ancient world. *Medical History*, 17(4), 391–399. <https://doi.org/10.1017/S0025727300019013>
- Waldron, T. (2009). *Palaeopathology*. Cambridge: Cambridge University Press.
- Walker, P. L. (2005). Greater sciatic notch morphology: Sex, age, and population differences. *American Journal of Physical Anthropology*, 127, 385–391. <https://doi.org/10.1002/ajpa.10422>
- WHO. (2010). *Childhood lead poisoning*. Geneva: WHO Document Production Services.
- Wibberley, D. G., Khera, A. K., Edwards, J. H., & Rushton, D. I. (1977). Lead levels in human placentae from normal and malformed births. *Journal of Medical Genetics*, 14(5), 339–345. <https://doi.org/10.1136/jmg.14.5.339>
- Woolley, D. E. (1984). A perspective of lead poisoning in antiquity and the present. *Neurotoxicology*, 5(3), 353–361.

SUPPORTING INFORMATION

Additional supporting information may be found online in the Supporting Information section at the end of this article.

How to cite this article: Moore, J., Filipek, K., Kalenderian, V., Gowland, R., Hamilton, E., Evans, J., & Montgomery, J. (2021). Death metal: Evidence for the impact of lead poisoning on childhood health within the Roman Empire. *International Journal of Osteoarchaeology*, 31(5), 846–856. <https://doi.org/10.1002/oa.3001>